

Acute appendicitis

John Simpson

John H Scholefield

Abstract

Acute appendicitis is the most common abdominal emergency and the overall lifetime risk in the UK is between 6% and 20%. The exact cause remains unclear, but luminal obstruction, diet and familial factors have been suggested, and the aetiology may be multifactorial in some cases. Inflammation of the appendix ranges from minor, simple acute inflammation to suppurative necrosis and perforation. The findings of history and examination can vary widely, and only about one-half of patients with acute appendicitis have a 'classical' presentation. Age can influence presentation and, because the appendix is a relatively mobile structure, the clinical picture is also dictated by the anatomical position of the inflamed organ. Due to the variability in presentation, there is a wide range of differential diagnoses when suspecting acute appendicitis and, although blood and radiological investigations may be requested, the diagnosis is often clinical. The first-line treatment for acute appendicitis in the UK is appendicectomy, which can be performed as an open procedure or laparoscopically. Wound infection is the most common complication of appendicectomy and rates vary according to the stage of disease and the degree of surgical contamination.

Keywords acute appendicitis, appendicectomy; appendix abscess; appendix mass; chronic (grumbling) appendicitis; emergency surgery; interval appendicectomy; laparoscopic; retrocaecal appendix; right iliac fossa

Acute appendicitis is the most common abdominal emergency and accounts for more than 60,000 hospital admissions every year in England and Wales. Appendicitis has an incidence of 1.5 (male) and 1.9 (female) per 1000 population per year in the UK; the overall lifetime risk is about 6–20%. Acute appendicitis is uncommon before the age of two years and rises to a peak incidence for a subject in his twenties or thirties (but no age group is exempt).

Aetiology

The vermiform appendix is a vestigial structure measuring 7.5–10 cm in length in an adult. Morphologically, it represents the underdeveloped distal part of the large caecum present in

John Simpson FRCS is a Lecturer in Surgery at University Hospital, Nottingham, UK. Conflicts of interest: none declared.

John H Scholefield FRCS is a Professor of Surgery at University Hospital, Nottingham, UK. Conflicts of interest: none declared.

many lower animals. The exact cause of acute appendicitis is unclear, but luminal obstruction, diet and familial factors have been suggested; the cause may be multifactorial in some cases.

Pathology

Inflammation of the appendix ranges from minor, simple, acute inflammation with spontaneous resolution to suppurative necrosis and perforation. Bacteria in the lumen are thought to initiate infection and bacteriological cultures from inflamed appendices usually reveal a mixed growth (commonly of *Escherichia coli*, *Klebsiella spp.*, *Proteus spp.* and *Bacteroides*). Organisms enter the wall at the site of an ulcer (usually caused by an impacted faecolith). If the inflammatory process progresses, the wall of the appendix becomes oedematous, and purulent inflammation leads to thrombosis and gangrene. The greater omentum and small intestine can adhere to the inflamed appendix and localize the sepsis, forming a phlegmonous mass or abscess. However, generalized peritonitis results if perforation occurs early in the inflammatory process. Perforation rates are 10–33% at the time of surgery in the UK general population, but these figures rise at the extremes of age.

Clinical features

The history and examination obtained can vary widely, and only about 50% of patients with acute appendicitis have a classical presentation as described below. Age can influence presentation and, because the appendix is a relatively mobile structure, the clinical picture is also dictated by the anatomical position of the inflamed organ. Patients may also present acutely with generalized peritonitis if the early stages of the disease are silent.

History (Table 1)

The primary feature is abdominal pain. Initially, referred pain is commonly felt in the central abdomen because of the visceral innervation of the midgut. In general, pain is colicky if there is

Clinical history and examination in patients with acute appendicitis

| | Reliable | Less reliable |
|-------------|---|--|
| History | Duration 24–36 hours Initial central location of pain and migration to RIF Anorexia | Vomiting Diarrhoea/ constipation |
| Examination | Tachycardia Mild pyrexia Guarding in RIF Percussion tenderness in RIF | Flushed Foetor oris Tenderness on rectal/ vaginal examination Rovsing's sign Psoas stretch sign Obturator test |

RIF: Right iliac fossa.

Table 1

appendicular obstruction or distension, but this pain tends to be more constant in non-obstructive cases. The pain intensifies and localizes towards the right iliac fossa as the inflammatory process continues and involves the parietal peritoneum. This usually occurs within 24 hours, after which the pain is described as sharp and aggravated by movement and coughing. Usually, following the onset of pain, loss of appetite and constipation are frequent and nausea is present. Patients may have vomited, although persistence of this symptom is not a common feature.

Examination (Table 1)

Usually, the patient is flushed with a dry tongue; an associated foetor oris is often present. Patients tend to be mildly pyrexial (up to 38°C) and have a slight tachycardia. There is muscular rigidity and percussion tenderness following localization of the pain in the right iliac fossa. Do not demonstrate rebound tenderness because it is unlikely to supplement the examination findings at this stage and can be extremely uncomfortable for the patient. In early appendicitis, pain can often be localized to the right iliac fossa by asking the subject to cough. Classically, the site of maximal tenderness is described as McBurney's point (which is the surface marking of the base of the appendix) and lies two-thirds of the way along a line drawn from the umbilicus to the anterior superior iliac spine (Figure 1). Palpation of the left iliac fossa may cause pain in the right iliac fossa (Rovsing's sign). Rectal and vaginal examination can be normal, although localized tenderness may be detected on the right side (particularly if the appendix lies within the pelvis).

Anatomical features influencing presentation (Figure 2)

Retrocaecal appendix – in this position, an inflamed appendix can be protected from the anterior abdominal wall by a caecum distended with gas. Muscular rigidity is often absent and tenderness to deep palpation is lacking. However, there may be tenderness in the right loin. The right hip may be held in a slightly flexed position due to psoas spasm because the inflamed appendix lies in contact with that muscle; passive extension or

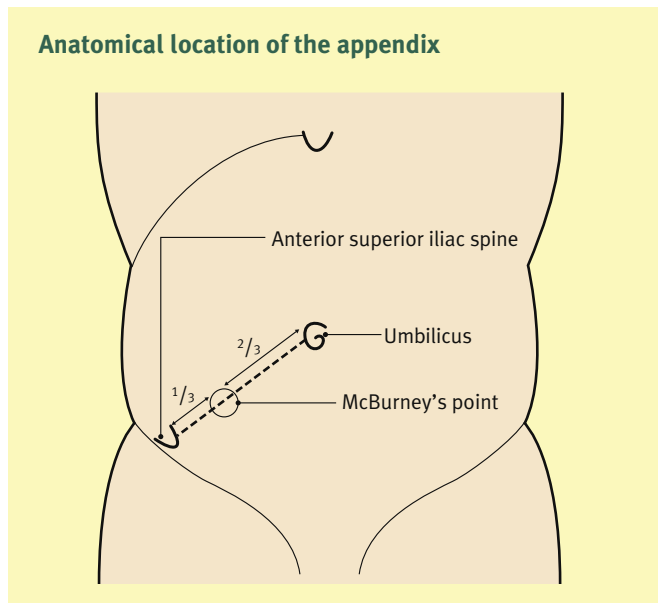
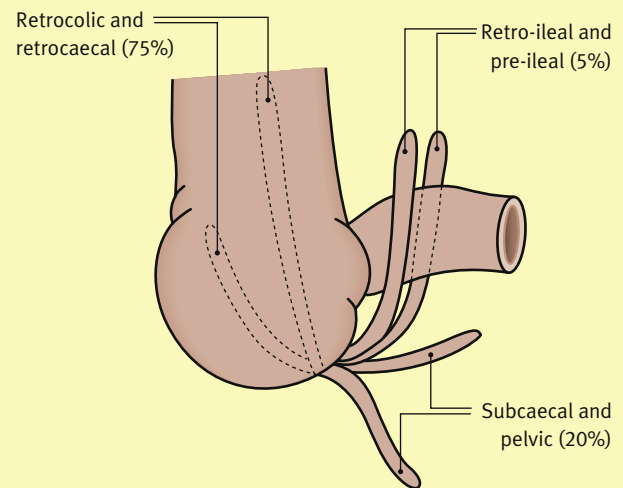


Figure 1

Anatomical positions of the appendix



Percentages refer to the approximate prevalence in the UK.

Figure 2

hyperextension of the right hip may increase the abdominal pain (psoas stretch sign).

Post-ileal – the inflamed appendix lying behind the terminal ileum can cause difficulty in diagnosis because the symptoms may be very vague and the pain is poorly localized because the inflamed appendix lies relatively protected from the anterior abdominal wall. Vomiting can be more persistent; diarrhoea is more frequent because the appendix irritates the distal ileum.

Pelvic – diarrhoea can be a prominent feature if the appendix lies in contact with the rectum. Contact with the bladder may lead to an increased frequency of micturition and microscopic haematuria. Tenderness may be lacking over McBurney's point (although rectal or vaginal examination may localize tenderness in the rectovesical pouch or the pouch of Douglas). Psoas spasm may be present, and passive internal rotation of the hip may aggravate the pain (obturator sign) if the appendix lies in contact with the obturator internus.

Age-related features influencing presentation

Young children – acute appendicitis in young children often has a non-specific presentation and difficulty in differentiating the condition from mesenteric adenitis or enteritis can result in a delay in diagnosis. This delay, along with the presence of an underdeveloped greater omentum (which can often fail to localize any developing sepsis), results in much higher rates of peritonitis, perforation and abscess formation; up to 75% of young children present in this way in the UK.

Elderly – symptoms are often less pronounced in the elderly, and these patients may be afebrile with a normal white cell count. Often, acute appendicitis is not considered in this age group and may be missed, resulting in a delay in treatment and higher rates of perforation (about 50% in the UK). These factors and their diminished physiological reserve contribute to the increased mortality in this age group.

Pregnancy: appendicitis occurs in 1 per 1500–2000 pregnancies per year in the UK and is the most frequent non-obstetric

indication for a laparotomy during pregnancy. Displacement of the appendix by the uterus during pregnancy can result in an atypical presentation and symptoms may be confused with the onset of labour. In contrast to the classical presentation, nausea and vomiting are usually more frequent and tenderness can be present anywhere along the right side of the abdomen due to the upward displacement of the appendix. However, tenderness may not be marked because the gravid uterus can protect the inflamed appendix from the anterior abdominal wall. Ultrasound is useful in distinguishing appendicitis from obstetric pathology. Simple acute appendicitis has a negligible maternal mortality, but the risk of foetal death is about 10% in the UK. However, perforation significantly increases the risks to the mother and the fetus, and the mortality rises to 2% and 30% respectively.

Investigations

Further investigations are not required in many cases of acute appendicitis. However, presentation can be variable and investigations are often required to exclude other causes of the symptoms.

Haematological: no single investigation will accurately diagnose appendicitis, but about 90% of patients will have a moderate leukocytosis (around 15,000 cells/ μ l), predominantly neutrophils (> 75%).

Urinalysis is usually normal, although patients with retrocaecal or pelvic appendicitis may have leukocytes or red blood cells in their urine (caused by irritation of the bladder or ureter by the adjacent inflammation). Urine microscopy and culture will identify a urinary tract infection if there are equivocal clinical signs.

A pregnancy test is vital in all women of reproductive age to exclude a gynaecological cause for the symptoms.

Imaging

Radiography – plain radiographs are unhelpful in diagnosis, but are used to exclude other causes of abdominal pain. Most of the changes seen in some cases of acute appendicitis (e.g. haziness in the right iliac fossa, dilated loops of ileum) are non-specific. However, abdominal radiographs can occasionally show an appendicular faecolith and, because up to 50% of children aged < 2 years have been reported to have a visible faecolith, a plain radiograph of the abdomen may be a useful diagnostic tool in this age group.

Ultrasound – high-resolution ultrasonography has a high sensitivity and specificity in the diagnosis of acute appendicitis. Ultrasound is not a routine diagnostic test, but it can obtain a diagnosis in patients with an atypical history and can be used to exclude other pathology (particularly in the female pelvis).

Laparoscopy allows good visualization of the abdominal and pelvic organs and is helpful in patients with an atypical presentation (especially young women in whom ovarian and tubal pathologies may result in a similar presentation).

CT has high sensitivity and specificity for the diagnosis of acute appendicitis. However, CT should be used with caution because

it requires significant exposure to radiation; it is rarely required to make a diagnosis of acute appendicitis.

Differential diagnosis

The variability in presentation in all age groups results in a wide range of differential diagnoses (Table 2).

Treatment

The first-line treatment for acute appendicitis is appendicectomy. In the UK, the operative mortality for early operation is < 0.2%, but rises to about 5% in the very young and elderly if perforation has occurred. In all cases, patients require adequate fluid resuscitation preoperatively (particularly in those presenting late with generalized peritonitis who may be severely dehydrated). Surgery may be delayed if an appendix mass can be felt preoperatively in an otherwise fit patient.

Appendicectomy

Open appendicectomy: classically, the appendix is approached through a muscle-splitting gridiron incision (Figure 3), which is made through McBurney's point perpendicular to a line drawn from the umbilicus to the anterior superior iliac spine. A Lanz incision (placed almost horizontally, low in the right iliac fossa, Figure 3) is also commonly used. The muscular layers of the anterior abdominal wall are split in the line of their fibres and the peritoneum exposed and opened. The caecum is identified and the appendix is delivered into the wound.

The abdominal wound should be extended to afford better access if there is difficulty in delivering the appendix. Mobilization

Differential diagnoses of acute appendicitis

| | |
|--|---|
| Thorax and respiratory tract | Pelvis |
| Tonsillitis | Ectopic pregnancy |
| Pneumonia | Ruptured ovarian follicle (Mittelschmerz) |
| Abdomen | Torted ovarian cyst |
| Intestinal obstruction | Salpingitis/pelvic inflammatory disease |
| Intussusception | Urinary system |
| Acute cholecystitis | Right pyelonephritis |
| Perforated peptic ulcer | Right ureteric colic |
| Gastroenteritis | Other |
| Mesenteric adenitis | Diabetic ketoacidosis |
| Terminal ileitis | Porphyria |
| Meckel's diverticulitis | |
| Colonic diverticulitis/appendicular diverticulitis | |
| | Rectus sheath haematoma |
| | Pancreatitis |
| | Preherpetic pain on the right 10th and 11th dorsal nerves |

Table 2

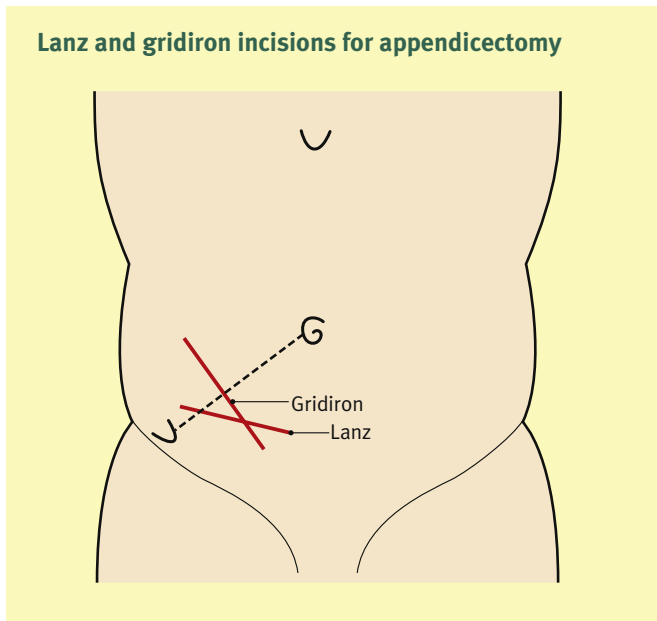


Figure 3

of the caecum (by dividing the peritoneal reflection along its lateral border) may be required if the appendix lies in a high retrocaecal position.

Once delivered, the appendicular mesentery is divided and the vessels ligated. The base is crushed, ligated and the inflamed appendix is removed. Inverting the appendicular stump or leaving it after ligation probably makes no difference. If free peritoneal fluid is present, lavage with warmed saline is usually performed and the wound is then closed in layers. A peritoneal drain is rarely necessary, although a corrugated or tube drain can be used if there is considerable purulent fluid in the retrocaecal space or pelvis. Perioperative broad-spectrum antibiotics (e.g. cefuroxime 750 mg i.v. and metronidazole 500 mg i.v.; 1–3 doses) should be used in all appendicectomies because they reduce postoperative formation of intra-abdominal abscesses and wound infection.

Laparoscopic appendicectomy: an increasing number of appendicectomies have been performed laparoscopically over the last few years. These are often combined with a diagnostic laparoscopy if the initial diagnosis is in doubt. Compared with open surgery, adult patients undergoing laparoscopic appendicectomy have a reduced:

- incidence of wound infections
- postoperative pain
- duration of hospital stay
- amount of time taken off work.

However, the incidence of postoperative formation of intra-abdominal abscesses is increased. Relative contraindications for this procedure are:

- complicated appendicitis
- patients with a high anaesthetic risk
- a previous history of extensive pelvic surgery.

The technique of laparoscopic appendicectomy should be undertaken only by surgeons with the appropriate laparoscopic

training. Port placement for the procedure varies, but usually involves a 10-mm port at the umbilicus and two 5-mm ports in the suprapubic region and left iliac fossa; some surgeons prefer one suprapubic port and one in the left iliac fossa. Once the pneumoperitoneum has been established, the operation continues as the open technique i.e. by:

- identification of the appendix
- division of the appendiceal mesentery with diathermy
- ligation of the appendicular artery with clips.

Once division of the mesentery is complete, the base of the appendix can be secured with an endoloop device, an extracorporeal knot or staple gun. Once transected, the inflamed appendix should be placed in a specimen bag before removal from the peritoneal cavity in order to prevent infection of the port sites. The indication for lavage, drains and antibiotics are as for the open procedure.

Postoperatively, patients are permitted to take fluid orally and diet is normally reintroduced within 24–48 hours. Antibiotics (i.v.) should be continued for five days for perforated appendices with advanced sepsis and generalized peritonitis. Following discharge from hospital, patients should avoid physical exertion for 2–3 weeks and then reintroduce activities gradually.

Postoperative complications

Wound infection is the most common complication and rates vary according to the degree of operative contamination. The infection rate is < 5% in low-risk cases with simple acute appendicitis, but can rise to about 20% if the appendix is gangrenous or if perforation has occurred. These rates can be reduced with the use of perioperative antibiotics and intraoperative peritoneal lavage. Delayed primary closure may be reserved for severely contaminated wounds.

Intra-abdominal abscess: gross peritoneal contamination can lead to formation of intra-abdominal abscesses postoperatively. The common sites are subphrenic and within the pelvis. Patients present with rigors and have a swinging pyrexia. Ultrasound examination is useful in diagnosis and the first-line treatment is drainage under ultrasound or CT guidance.

Faecal fistula is a relatively rare complication and occurs from the appendix stump; it can result from an insecure ligature or caecal ischaemia. Most settle with conservative management.

Appendix mass

A tender mass can often be felt in the right iliac fossa if there is a delay in presentation. There is overlying muscular rigidity, but otherwise the abdomen is soft and non-tender. The mass consists of an inflamed or perforated appendix surrounded by the greater omentum, caecum and adherent loops of small intestine. Conservative treatment is indicated for patients with an appendix mass who are otherwise clinically well and stable. They are observed closely, kept nil-by-mouth and treated with antibiotics (cefuroxime 750 mg i.v. and metronidazole 500 mg i.v. t.d.s.). Surgery is indicated if the patient shows signs of increasing

peritonitis or becomes systemically unwell; in general, over the next few days, the rigidity settles and the limits of the mass can be clearly defined. Subsequently, the mass resolves as the inflammation settles or increases in size as an appendix abscess develops.

Appendix abscess

Patients with an appendicular abscess have a swinging pyrexia and tachycardia. Abscesses are most commonly found in the lateral aspect of the right iliac fossa or within the pelvis. Abscesses can occasionally be detected on abdominal palpation, but rectal and/or vaginal examination is vital in order to identify a pelvic collection. Blood tests show a polymorphonuclear leukocytosis and accurate diagnosis can be obtained using ultrasound. The abscess can be drained radiologically with CT or ultrasound guidance or as an open procedure (which allows an appendicectomy to be performed simultaneously).

Interval appendicectomy

Following successful conservative treatment of an appendix mass or abscess, some surgeons in the UK advocate an elective appendicectomy because it eliminates the possibility of further attacks. However, the variability of recurrence rates (10–35%) makes its role controversial.

Chronic (grumbling) appendicitis

Chronic appendicitis and its relationship to persistent right iliac fossa symptoms must be investigated fully and chronic appendicitis should remain a diagnosis of exclusion. In certain situations, appendicectomy can lead to the resolution of such symptoms and the appendices are found histologically to be chronically inflamed, fibrotic and may have altered sensory neuropeptide staining. Whether these findings result from ongoing chronic inflammation or repeated bouts of acute inflammation remains uncertain. ◆